

Prevalence of Uterine Cervix Cancer in Kenya, a Major Social economic Challenge on Health Goal

¹Maurice B Silali* and ²Emily Rogena

¹Department of Human Anatomy, Maseno University, ²Department of Anatomic Pathology, Nairobi University
gmsilali@yahoo.com

Abstract

Uterine cervical cancer is a leading health problem among women. Majority (70%) cases are confined in Sub Saharan Africa (SSA), mainly associated with Human Papilloma Virus (HPV) of genotypes 16 and 18. Generally 85% of uterine cervical cancers are squamous cell cancers while, rest are adenocarcinomas. In Kenya majority of affected women never recognize this cancer for many years because of its silent clinical presentation. While in Developed countries the cancer is detected early due to accessible sustainable screening programs. Prolonged limited access to affordable and quality differential diagnosis, HPV antigen tests, and persistence low coverage screening programs in (SSA) have led to high levels of morbidities and mortalities associated with uterine cervix cancer which has impacted negatively on social economic and health Development in (SSA). It was these reasons that led to determine prevalence of uterine cervix cancer, a major challenge on health goal, using Pap stains in Kenyatta National Hospital, (KNH). In cross-sectional, 400 respondents were used in saturated sampling. Data was collected and analyzed from Pap slides and mounted in DPX mountant before microscopic differential report concluded. Results, 48% of women seeking healthcare in (KNH) were infected with HPV genotype 16 and 18 that cause cancer of cervix, Nevertheless prevalence of other related health risks in uterine and cervix fluctuate gradually. Women cohabiting HPV gene 16 and 18, have greater risk to develop cancer of cervix than to women with physically warts on vulva, with OD (4.9, 0.02) 95% CI (1.5, 0.3). Recommend primary prevention than cure

1.1 Introduction and Background Information

The *cervix* is a lower, narrow end of uterus that connects the vagina to the uterus where a baby grows when a woman is pregnant. *Cancer* is a disease in which cells in the body grow out of control. Uterine cervical cancer is one of the leading causes of deaths in women, though is highly preventable when detected early globally. In developed countries like America and Britain, epidemics have reduced greatly due to ease availability, accessible and affordable quality screening methods of Pap tests, HPV antigen tests and HPV vaccines, CDC, cervical cancer, (2015), that have enabled them to eradicate and control Human Papilloma virus, which associated with spread of cancer of the cervix in the health population, American Cancer Society,(2016). However availability and sustainability of these quality services in Sub-Saharan Africa remain a big challenge to influence eradication and prevention of uterine cervical cancer, like in Kenya among the reproductive cohorts attending reproductive healthcare in Kenyatta National hospital, a regional referral facility in East and Central Africa. When uterine cervical

cancer is found early, it is highly treatable and is associated with long life survival, CDC, cervical cancer, (2015).

Studies by Gosforth, show that majority of uterine cervical cancer is caused by Human Papilloma Virus (HPV) through sexual contact, Gosforth, (1953). There are many types strains of the HPV virus, genotype 16 and 18, attributed with HPV virulence, Mac ween, (1992). Not all types of HPV genes cause uterine cervical cancer, but some genes are associated with development of genital warts. Prevalence of silence signs and symptoms of women infected by cancer of uterine cervix remains a major social economic challenge in Sub-Saharan Africa. Pap tests may indicate any form of neoplasm in uterine cervical cells, before they develop into cancer, when these cellular changes are detected and treated early, will prevent the spread of infective cancers to distant tissues and organs, Forman (1974). There are two major types of cancers that develop from infective uterine cervix: Squamous cell cancers arise from the squamous epithelium that covers the visible layer of the cervix. Adenocarcinomas arise from glandular lining of endocervical canal, Gilbert, (1966). Majority (85%) prevalence of uterine cervical cancers is mainly associated with squamous cell carcinomas and remainders are adenocarcinomas. Squamous cell carcinomas are unique because there is well established progression through premalignant changes before develop into neoplasm. These premalignant changes are easy to detect by a simple screening test called Pap test which use Pap stains that form a bench map of cytological screening and diagnosis of cancerous conditions of the vagina, cervix and endometrial, Papanicolau, (1948).

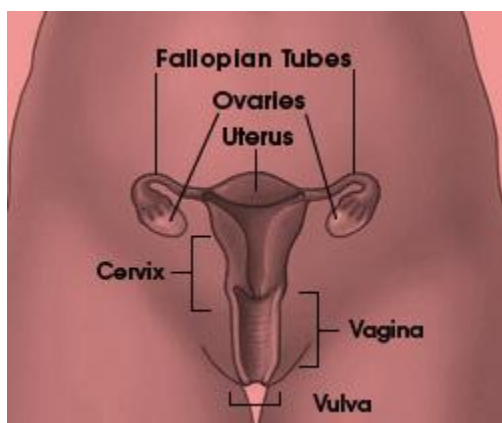
Pap smear screening means testing for the presence of any cancerous lesion, before any symptoms appear or findings are made on examination. The major benefit of the Pap test is to detect changes on the cervix before they become cancerous. Pap test also, assesses sex hormonal function and other type of inflammations, Papanicolau, (1948). Cervical cancers can spread by way of the lymphatic system, Bibbo, (1971) Uterine cervical cancer is highly preventable in most developed countries because majority of reproductive cohort, are readily accessible to affordable HPV vaccines, quality screening tests that influence easy prevention and eradication of Human Papilloma virus among the population, However these services still remains big challenge to communities in (SSA). When uterine cervical cancer is found early stage, it is easily treatable and associated with long life survival, CDC, cervical cancer, (2015).

Invasive epidermoid or squamous cancer of uterine cervix developed from abnormal cancerous of the surface epithelium which are classical form of cancer in situ, invasive cancer may also originate from related epithelial lesion with lesser degree of histological abnormality called border line lesion or dysplasia. Cancer of uterine cervix have received great attention as model of human cancer genesis due to large degree of frequency lesion of cytological abnormality and histological abnormality sampling and accessibility of cervix to inspection by colpscope and its research microcolpscope, Mac ween, (1992). Female wearing IUDs have mechanical effect on the endocervical epithelium that may result to shedding of endocervical epithelium to form endocervical cells with distended vacuolated cytoplasm, Koss, (1959), the vacuoles may infiltrate by polymorph nuclear leucocytes. Continued persistence of limited access to quality Pap tests screening and affordable HPV antigen test typing among the reproductive cohorts in Sub Saharan Africa have posed a major challenge towards the achievement of quality and sustainable global health by 2030.

2.0 Methods and Materials

2.1 Histology of Uterine Cervix an Aid in Differential Diagnosis

Uterine cervix is a muscular tube measuring 40mm by 30mm in diameter, half of it is located in the vagina and the rest is embedded within the vaginal wall. Anatomically the cervix is close to urinary bladder thus easily involved in urinary tract by cancer. Uterine cavity within the cervix is called endocervical canal which is continuous with endometrial cavity of corpus, Sonek, (1968). The external os, an opening of cervical into vagina and internal os point a transition of endocervical canal into endometrial cavity. Cervical canal is narrow to most 20-30 mm diameter. Internal os start with fallopian tube and lumen of endometrial cavity in the resting stage is quite small. Epithelial cells during their child bearing, stratified squamous cells of the cervix and vagina from labia minora and adjacent vagina level of lumen they originate from urogenital sinus, which form vaginal portion of the cervix derived from mullein duct by transformation metaplasia of cubidal into squamous epithelial ,Mac ween,(1992).



Source: CDC cervical cancer, (2015)

Histology during sexual maturity has 3 layers observed with squamous epithelia, Sonek, (1968), basal layer in the main source of constant epithelium regeneration, mid zone forms the bulky epithelia thickness and superficial zone, the germinal or basal layer consist of small elliptical cells measuring 12microns in diameter, nuclei show active cellular growth and mitosis ,under normal process the entire process of epithelia regeneration occur only on the basal layer, while remaining zones serve as the stage of cell maturation, Sonek, (1968). Mid zone is very wide and compose of mature squamous cells bound to each other by well developed desmosomal attachment or inter cellular bridges as the maturation of progress to the surface, amount of cytoplasm per cell increase while the size of the nuclei remain constant, Sonek, (1968). Para basal cells are smaller cells of the deeper portion of the mid zones; intermediate cells are larger cells adjacent to superficial zones mid zones form surface of squamous epithelial cells, mid zones form surface layer of squamous epithelial cells when more maturation is being arrested in various abnormal conditions,. Superficial zones consist of several layers of loosely attached cells that are larger than intermediate cells, nuclei are smaller and pyknotic and completely matured, are naturally casted off from epithelial surface by desquamation or exfoliative mechanism by either single or in cluster squamous cell, Sonek, (1968). Cluster cells are bound are bound by desmosomes and exfoliation mechanism by either single or in cluster squamous cells. Cluster

cells are bound by desmosomes and exfoliation is thought to be due to splitting of desmosomal bounds and other attachment is active by protein enzymes. Cytoplasm of superficial cells contain protein bound disulfide which indicate presence of precursors of keratin , full development of keratin occur only during abnormal epithelium conditions, squamous epithelial cervix and vagina are rich in glycogen, maturation of epithelial cells takes 4 days, differentiation process are accelerated for 39 to 45 hrs by administration of estrogen, NHS,(2014). The main supports of squamous epithelium are connective tissue stroma and blood vessels bearing projections of connective tissues (papillae) that supply nutrient to the cells, Gilbert, (1966). The basement membrane is found underneath of basal layer of endocervicals mucosa and gland surface of squamous epithelia cells is provided with network of short uniform micro ridges for fitting on each other, Gilbert, (1966).

Cells originating from normal squamous epithelial cells are of cervix and vagina are superficial squamous cells seen during child bearing span of life in cervical and vaginal smears , the term is reversed only for large cell polygonal shape with flat delicate transparent cytoplasm and small pyknotic nucleus surrounded by clear zones, Papnicolaou,(1948). Flat surfaces are provided by microridges in Pap stain superficial cells cytoplasm stain delicate pink which reflect chemical affinity of cytoplasm for acidic dyes eosin, thus eosinophilic dryness to air and to enhance eosinophilic properties of the cell, sometimes cytoplasm stain pale blue due to slight affinity for basic dye haematoxyline, Papnicolaou,(1948). The staining property of cytoplasm depends on state of maturation of the cell. Eosinophilic are most matured cell, the small dark brown granules are seen in cytoplasm of superficial cells in case of perinuclear location seen as periphery of the cytoplasm, nuclei of superficial are always pyknotic (condensed and shrunken), karyorrhexis (fragmentation of pyknotic nucleus) seen in vicinity of main nuclear mass, nuclear pyknosis indicates last stage of squamous maturation, Papnicolaou, (1948). Complete maturity of squamous epithelia cell is achieved in presence of active estrogen; nuclear pyknosis in mature superficial cell constitutes excellence morphologic evidence of peak estrogen activity, Papnicolaou, (1948).

Intermediate squamous epithelial cells have same size has as superficial cells or smaller ,cytoplasm is basophilic and in Pap stain , main difference between above two is that nucleus of intermediate cells measures above 8microns in diameter ,oval round with clear defined nuclear membrane surrounding nucleoplasm. Chromatin, chromo centers may be seen as nuclei, thus the term vesicular nuclei. Common unique cells seen in intermediate cells are presence of navicular nuclei which are elongated and boat shaped cells. Navicular cells play important roles in cytology of pregnancy women where they become filled with glycogen deposit. Intermediate cells dominate majority of population in Pap test due to pathological or physiological conditions, inflammations, hormonal defect, pregnancy or menopause, Intervention congress, (1956)

Para basal cells are rarely seen in normal smears of child bearing female age ,may seen in female above 35years, in pathologic conditions smears of these cells increase significantly from 12 to 30micron in diameter and cytoplasm stain blue, Sonek.(1968) and contain small vacuoles , which when exposed to air may cause to air dryness thus cytoplasmic eosinophilic and para cells are round or oval in shape with smooth cytoplasmic following death, if parabasal cells are forced they dislodge from their epithelium setting and fixed rapidly to intracellular bridges inform of cytoplasmic processes , may noted in clusters of angular and irregular polygonal shapes and its cytoplasm is round or oval due to contraction and cell death before fixation, Baker and Silverton, (2001)

Basal cells have a protective state hence rarely seen practically in smears, they are only seen due to pathological conditions as tiny round or oval cells which resembles the parabasal cells with basophilic cytoplasm with scanty and slightly large nuclei, display chromatin granules with nucleoli. The squamous columnar junctions also called transformation zone is an area where genes of cancer of the cervix begin and it lies between squamous and endocervical epithelia, Sonck, (1968).

2.1.1 Pathogenesis

Cancer of uterine cervix is leading health condition in morbidity and mortality among most married women. Epidemiologic factors that influence the spread of cancer of the cervix include young age at first sexual intercourse promiscuity or multiple of marital partners and multiple births in the first exposure of occurred early in life, Documentation show that women who have sex in their teens, multiple sexual partners and multiparous at early age are at greater risk of developing cancer of uterine cervix than women who begin their sexual activity later and have marital partners, Mac ween, (1992).

Lack of enough professional cytology expertise or diagnostic laboratory support in cancer diagnosis has lead to significant scaling of this problem in (SSA). Study by world health organization (WHO), show that most female who attend medical checkup of their genitalia, may contain mostly unknown infection or infestation by micro biological organisms such as bacteria, parasites, viral and fungi which cohabit mostly in mean and modal class of sexual active reproductive women rather than suspected squamous intraepithelial lesions, Koss, (1959). In female wearing IUDs most Pap test may showed reactive slides with few cases of fungal infection, Forman,(1974). Majority of lesions obtained were associated with Human papilloma Virus, (Gosforth, 1953) of low grade squamous, intraepithelial lesions,(LSIL) and High grade squamous intraepithelial lesions (HSIL),with positive HPV antigen test whose genotyping were mainly gene 16 and 18, Mac ween, (1992).

Adenocarcinoma of the endocervix is caused by endocervical polyps that do originate in endocervical canal; polyps contain a central connecting tissue stalk lined by gland forming endocervical mucosa. Squamous metaplastic epithelium may replace portion of the outlining and extend to the gland. Inflammatory phenomena of varying degree of intensity are observed in stroma, polyps cause abnormality of squamous cells like small highly keratinized cells with large pyknotic nuclei, William, (2014). Squamous papillary lesion of the cervix and vagina are grouped into two groups' mainly solitary squamous papiloma, Gilbert, (1966) and condylomata acuminated (venereal warts). Condylomata acuminata are sexually transmitted papillomas caused by virus of Papova group, Koprowsk,(1975), which occur in multiple and numerous number and attack skin of perennial area, vulva, in female and gland penis in male, commonly attack vagina and cervix, Koprowsk,(1975),

2.2.1 Uterine Cervical Cancer during Pregnancy

In general, the pregnancy has no effect on the cervical problem and the cervical problem has no effect on the pregnancy. However, the cervix is best not manipulated or biopsied during the first trimester because the risk a spontaneous miscarriage is about 20%. Should this happen, the

biopsy will be blamed, although it will not have been the cause. There is no urgency to diagnose a premalignant condition during pregnancy, France, (1988). All that is really necessary is to exclude or diagnose an invasive cancer. Often this can be accomplished by a colposcopic examination, without the need for any biopsy, William, (2014). The premalignant conditions can easily wait until 6 weeks after the baby is born to evaluate and treat. Sometimes however, biopsies and even cone biopsies must be done. The best time for these biopsies is the early second trimester because the risk for a spontaneous miscarriage has past and cervical manipulation during the third trimester risks premature labor. If an invasive cancer is diagnosed during pregnancy, the treatment is the same as for those not pregnant except, treatment can be delayed until the baby is sufficiently mature to be delivered, if the diagnosis is made after the 24th week of pregnancy. The baby will usually reach lung maturity sometime between the 32nd and 36th week, William, (2014)

2.2.2 Clinical Effects of Uterine Cervical Cancer

Most tumors, both benign and malignant do not necessary produce symptoms of illness for many years as many people have been found through screening programs, Mac ween, (1992). Majority of women without symptoms are attributable to their cancers which are detected through prevalence of abnormal cells in uterine cervical smears. Cancer produces a great range of clinical effect that helps in recognition, hence lead to diagnosis treatment and control, Koprowsk, (1975)

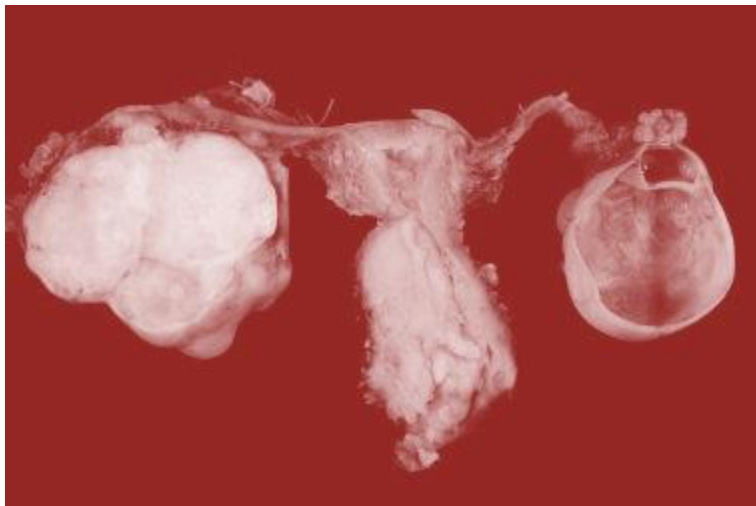
2.2.3 Local and Metastatic Effect S of Uterine Cervical Cancer

Benign and malignant tumors occupy spaces on the midst of loose connective tissues, and obstruction that produce stasis upstream and are often associated with infection. Obstructive effects of malignant are destructive with commensurate loss of function, vascular effect can be prominent, many cancers bleed from their surface to cause chronic blood loss that result to Iron deficiency anemia IDA, Mac ween, (1992). Spaces occupying effects intensify with suddenness of hemorrhage within the growth. Most cancers deaths occurring after treatment are due to effect of metastatic rather than failure to control tumor at primary site effect of metastasis repeat those of primary tumors but multiply at the site, metastases I, uterine cancer may cause iliac pain and pathological fracture, William (2014)

2.2.4 Cancer Progression

Describe stepwise acquisition of more aggressive properties by tumor during growth, Benign tumor may become malignant when intra epithelial neoplasia develop with more abilities to penetrate the basement membrane and grow by infiltration. Cancer cells, which were previously sensitive to drugs, may become resistant, FDA, (2016). Tumor progression is manifested of the fact that tumor cells consist of genetically unstable, proliferating cells. Sub populations with new properties are constantly generated and if they posses growth, the advantages goes to quickly adopted cells leading to defined cancer cells character, Bibbo, (1971)

2.3 Physiological Cellular Changes



Cervical carcinoma Source: American Cancer Society, (2016)

Cellular changes due to cancer of cervix are densely packed with cluster cells of endocervical observed in aversion scrape smear, clinical findings of leucoplakia, a white patch of discoloration of the cervix which is due to abnormal keratin formation of surface of sq. epithelium of the cervix, France, (1988). In majority cases of benign, lesions may cause trauma, prolapsed of uterus, or cauterization of the cervix. A nuclearlated sq. epithelium of yellow color shed from keratin sq. epithelium. Presence of atypical cell in micro glandular hyperplasia, endocervical polyps with irregular dense nuclei, nuclear enlargement without increase of the overall size and shape, hyper chromatin particles, small anaplastic cells with Bizarre mitotic figures squamous pears cells, epithelial stratification keratin forming sq. type of cells with single keratinized cells, Gosforth, (1953). Almost all cases of cervical cancer are caused by the Human Papilloma virus (HPV), are transmitted by heterosexual contact. There are more than 100 different types of HPV genotypes, many of which are harmless. However, some are associated with abnormal changes of the cells of the cervix, which lead to cervical cancer. Two strains of the HPV virus (HPV 16 and HPV 18) are known to be responsible for 70% of all cases of uterine cervical cancer. These types of HPV strains never give any symptoms; so many women won't realize they have the infection, France, (1988).

However, it's important to be aware that these infections are relatively common and most women who have them don't develop uterine cervical cancer. Using condoms during sex offers some protection against HPV, but it can't always prevent infection, Forman, (1974), because the virus is also spread through skin-to-skin contact of the wider genital area. HPV can be transmitted sexually, so there is an association with multiple sexual partners and early age coitus. The strongest association, however, is that women who have been celibate all their lives almost never develop squamous cell cancer of the cervix, but have risk to develop adenocarcinoma of the endocervix. HPV changes are often noted on Pap test report and should not cause alarm, Koprowsk, (1975). If there are any premalignant changes diagnosed then they will be treated.

2.4 Screening of Pap Tests

Over the course of many years, cells lining the surface of the cervix undergo a series of changes. In rare cases, these precancerous cells can become cancerous. However, cell changes in the uterine cervix can be detected at a very early stage and treatment can reduce the risk of cervical cancer developing. The NHS offers a cervical screening programme to all women from the age between 17 and 65 years. During uterine cervical (Pap smear) screening, a small sample of cells is taken from the cervix and checked under a microscope for abnormalities. An abnormal cervical screening test doesn't mean you definitely have cancer. Most abnormal results are caused by an infection or the presence of treatable precancerous cells, rather than cancer itself, NHS, (2015). Women aged 25 to 49 years of age are offered screening every three years, and women aged 50 to 64 are offered screening every five years. For women who are 65 or older, only those who haven't been screened since they were 50 or those who have had recent abnormal tests are offered screening.

Screening means to test for the presence of a cancer before there are any symptoms or findings on examination. If there are symptoms or abnormal findings on examination then a diagnostic test must be done; not a screening test. The major benefit of the Pap test is to detect changes on the cervix before they develop cancerous. These premalignant changes are referred to as dysplasias or as intraepithelial neoplasias. They are easily and effectively treated, Gilbert, (1966). When a Pap test is reported as abnormal a well established evaluation is begun. Only after this evaluation is completed can a diagnosis be made as to the true condition of the cervix. Only after the diagnosis is established can treatment be recommended. It is a major mistake to treat on the basis of an abnormal Pap test without a diagnosis. Specimens for cytological examination are obtained by vaginal speculum examination or colposcopy with biopsy, material from cervix endocervix and posterior fornix are obtained as pap tests. Pap tests for hormonal evaluations are obtained from the lateral wall of the vagina, NHS, (2015).

2.5 Pap test Normal References

Papnicolau Maturation Index (MI) is the ratio of Para-basa to intermediate to superficial cells in normal Pap smear of female reproductive system, Sonek, (1968)

Normal child female	80:20:0
Pre ovulatory adult females	0:40:60
Pre-menstrual adult female	0:70:30
Pregnant adult female	0:90:10
Post menopause Adult	65:30:15

2.6 Common Challenges During Pap test Preparation.

- i. Medical lubricants smeared on speculum may interfere with quality of results produced. Remedy apply saline or distilled water on speculum before inserting into cervix
- ii. Presence of wash off and floater on slides and stain. Remedy filter reagents to remove washed off cells to control floaters from washed off cells obscuring cells due to poor fixations, Baker and Silverton, (2001).
- iii. Formation of precipitants on slides and debris on stained slides due to use of unstained dyes Harris hematoxyline and EA36. Remedy filter reagents to remove washed off cells. France, (1988).
- iv. Slides with Stained background that obscure cellular components due to use of dirty slides. Remedy use clean and grease free slides, Baker and Silverton, (2001).
- v. Slides with crashed effect, which distorts cell morphology due to use of too much force when making smears. Remedy, prepare smears gentle always using minimal force.
- vi. Confluxes (Brown debris) on slides formed due to exposure of slides in air for longer period during staining. Remedy, concentrate on work during staining period.
- vii. Air bubble on slide, after slide mounting caused by too little or too light DPX mountant used. Remedy, use correct volume of mountant and employ good mounting techniques, France, (1988).

2.7.1 Signs and Symptoms of Cervical Cancer

Women with early cervical cancers and pre-cancers usually have no symptoms. Symptoms often do not begin until a pre-cancer becomes a true invasive cancer and grows into distant tissue, the most common sign and symptoms of uterine cervical cancer include:

- i. Abnormal vaginal bleeding, such as before or after sex (vaginal intercourse), bleeding after menopause, bleeding and spotting between periods, and having longer or heavier (menstrual) periods than usual. Bleeding after (douching), washing inside the cervix or after a pelvic exam is a common symptom of cervical cancer but not pre-cancer.
- ii. An unusual discharge from the vagina, a discharge may contain some blood and may occur between your periods or after menopause.
- iii. Pain during sex (vaginal intercourse).

These signs and symptoms are also associated with other health conditions rather than uterine cervical cancer, France, (1988). For example, fungal infection can cause pain or bleeding. Still, if you have any of these problems, you should see your health care professional right away: even if you have been getting regular Pap tests. If it is an infection, it will need to be treated. If it's cancer, ignoring symptoms might allow it to progress to a more advanced stage and lower your chance for effective treatment. Even better, don't wait for symptoms to appear. Be screened regularly, Gilbert, (1966).

Women with early cervical cancers and pre-cancers usually have no symptoms. Symptoms often do not begin until a pre-cancer becomes a true invasive cancer and grows into nearby tissue. When this happens, the most common symptoms are: Bleeding from the vagina that is not normal such as bleeding between menstrual periods, after sex, or after menopause, pain in the

lower belly or pelvis and pain during sex. Even better, don't wait for symptoms to appear. Be screened regularly, Baker and Silverton, (2001). There may be no symptoms of a very early cervical cancer, but by the time it is large enough to detect visually it is usually symptomatic with abnormal bleeding. Often this abnormal bleeding occurs after sexual intercourse. Cancers must make new blood vessels as they grow. These new blood vessels are often abnormal and break easily which is why bleeding is a sign of cancer. The cancer also outgrows some of its blood supply, so portions of it are deficient in oxygen. This causes some of the cells to die and for the tissue to become infected. In the cervix this causes a watery or foul discharge that will be noticeable and resistant to most treatments for the usual vaginal infections. As the cancer increases in size it usually grows laterally toward the pelvic wall. The tubes from the kidneys (ureters) that bring urine to the bladder pass through this area and they are easily obstructed. If that happens to both of the ureters, then this will result in renal failure, coma and death. If the cancer grows into the pelvic wall it will press on the nerves that go to the leg and cause unremitting leg pain. These are symptoms of an advanced cancer. Premalignant changes have no symptoms and are usually not noticeable on visual examination, Wiliam, (2014)

Cervical cancers usually do not spread early. They tend to be slow growing and cause most of their problems in the pelvis. Although distant metastases occur they are usually late events. Cervical cancers can spread by way of the lymphatic system. The lymphatic vessels drain from the cervix to clusters of lymph glands along the pelvic wall. The lymphatic follow the large blood vessels so the route of drainage is upward along the pelvic wall, then along the midline of the backbone and then to the chest. If the pelvic lymph nodes on one side of the pelvis become obstructed with cancer then that will cause swelling in the leg on that side. This is another sign of advanced cancer, U.S Cancer statistics, (2016).

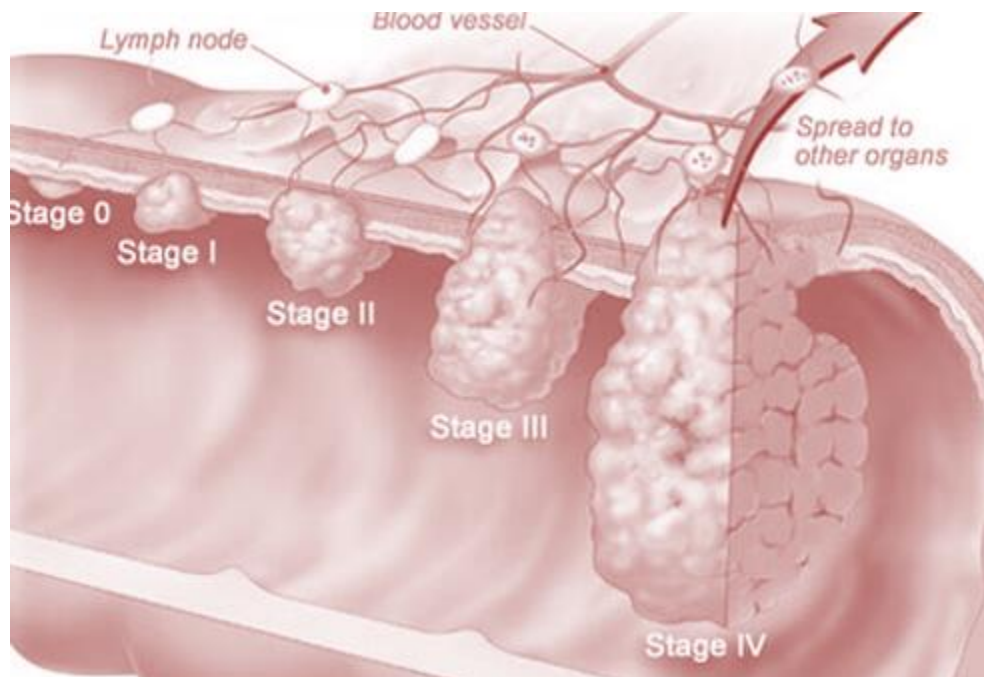
2.7.2 Physical Symptoms of Cervical Cancer

- i. Abnormal vaginal bleeding
- ii. Vaginal discomfort
- iii. Malodorous discharge
- iv. Dysuria

2.8.1 Diagnosis and Biopsy

The diagnosis of cervical cancer is usually not difficult. It is usually big enough to be seen and can be biopsied. If it arises from up inside the cervical canal then it may not be visible. This will require that a portion of the cervix be removed for diagnosis, France, (1988). These large biopsies can be accomplished by either a LEEP or cone procedure. A major mistake is to rely on a Pap test to rule out a cancer in a woman who has symptoms or findings that could be due to a cancer. A normal Pap test never excludes a cancer. Cancer can only be excluded by the proper biopsies, Mac ween, (1992). It is known that about 10% of women with an obvious cancer of the cervix will have a Pap test that is essentially normal. This is because there is so much inflammation and dead cell debris that it masks the cancer cells. Very rarely, the cervix may be too small or inaccessible to biopsy properly. In these situations a simple hysterectomy may have to be done for diagnosis, France, (1988).

2.8.2 Clinical Stages of Cancer of Cervix



Source: U.S Cancer statistics, (2016)

Staging is the process of determining how far cancer has spread beyond its original location. Staging may not be related to size of tumor. For uterine cervical cancer this is determined by physical examination, CT scans and MRI scans. Likewise, surgical exploration is not used to assign a clinical stage but treatment decisions are determined by the stage of cancer. Staging for uterine cervical cancer is as follows:

- i. Stage 0 – The cancer of the cervix is found in the innermost lining only
- ii. Stage I – The cancer of uterine cervix has not spread beyond the inner wall.
- iii. Stage II – The cancer uterine cervix has spread into the muscle layer of the organ.
- iv. Stage III – The cancer of uterine cervix has spread into lymphatic system
- v. Stage IV – The cancer has metastasis to distant sites in the body, such as vagina , bones, liver, or lungs, American Cancer society,(2016)

2.8.3 Prognosis and Recurrence

Most early cancers are cured; most advanced cancers are not. If cancer was removed surgically then it cannot come back. If it recurs that means that cancer cell had already spread by the time the cancer was being removed, and it took a couple of years to grow large enough to be detected. If uterine cervical cancer is destined to recur, about 85% will recur within the first two years after treatment. If there has been no recurrence by five years, then the cancer is unlikely to recur and is considered cured, Mac ween, (1992).

If the cancer recurs then the outlook is generally poor. If initially operated, then the recurrence can be treated with radiation. If initially irradiated then sometimes ultra-radical surgery can still be curative. If there is a recurrence in the cervix or vagina after the pelvis has been irradiated and there is no evidence of cancer anywhere else, then ultra-radical surgery can be done. This is called a total pelvic exenteration. The uterus, tubes, ovaries, bladder, colon and vagina are removed. Sometimes the vagina can be reconstructed and the colon reattached. A continent urinary reservoir can also be done, Bibbo, (1971)

Isolated recurrences elsewhere such as lung or liver can be removed surgically or irradiated if not removable. The treatment of isolated recurrences can be curative since cervical cancers do not usually spread widely throughout the body. Chemotherapy for recurrent cancer has not been very effective, but is often tried, CDC, (2015)

2.9 Treatment

2.9.1 Stage-Based Treatment

The treatment of uterine cervical cancer varies with the stage of the disease, as follows:

- i. Stage 0: The cancer of the cervix is found in the innermost lining only, may be treated with local ablative or excision measures such as cryosurgery, laser ablation, and loop excision or surgical removal.
- ii. Stage IA1: The cancer of uterine cervix has not spread beyond the inner wall, the treatment of choice may be surgery; total hysterectomy, radical hysterectomy, and conization
- iii. Stage IA2, and IIA, The cancer of uterine cervix has not spread beyond the inner wall, we may use a combined external beam radiation with brachytherapy and radical hysterectomy with bilateral pelvic lymphadenectomy for patients with stage IB or IIA disease; radical vaginal trachelectomy with pelvic lymph node dissection is appropriate for fertility preservation in women.
- iv. Stage IIB, III, or IVA, the cancer of uterine cervix has spread into, muscle, lymphatic system and metastasis' to distant tissues and cells, Cisplatin-based chemotherapy with radiation is the standard of care
- v. Stage IVB The cancer has metastasis to distant sites in the body, such as vagina, bones, liver, or lungs, and recurrent cancer: Individualized therapy is used on a palliative basis; radiation therapy is used alone for control of bleeding and pain; systemic chemotherapy is used for cancer management, American Cancer society, (2016), FDA,(2014),

In radical hysterectomy, the cervix is removed to stay as far away from the cancer as possible. A regular or simple hysterectomy is used to remove the cervix from affected tumor. Cancer surgery requires that we remove cancer with as good a margin of uninvolved tissue. The radical hysterectomy technique removes all supporting ligaments to the cervix which means that the dissection is very close to the bladder and to the rectum. The ureters have to be dissected out and the tissue around removed. A radical hysterectomy with removal of the lymph nodes takes about 4 hours to perform. A simple hysterectomy takes only about 1-2 hours. The ovaries may not be part of the problem then can be left in place. If after surgery pathology indicates reactive lymph nodes or

that the surgical margins are close, then pelvic irradiation with or without chemotherapy may be advised,' FDA, (2014)

For Ultra radical pelvic surgery for advanced or recurrent cancer, all the pelvic organs are removed, that is uterus and cervix, vagina, bladder and rectum are removed. Sometimes vagina can be reconstructed and if rectum is reattached then there will be no need for a colostomy. Sometimes a continent urinary reservoir can be constructed, Bibbo, (1971). Otherwise a bag will have to be placed for the urine to drain through an ostomy in the abdominal wall. This ultra-radical surgery is done if there is an extensive cancer involving the bladder or rectum, but without spread beyond these structures. It is also done for cancers that recur after pelvic radiation if they are confined to the pelvis, Bibbo, (1971).

If cervical cancer is diagnosed at an early stage, it's usually possible to treat it using surgery. In some cases, it's possible to leave the womb in place. The surgical procedure used to remove the womb is called a hysterectomy. Radiotherapy is an alternative to surgery for some women with early stage cervical cancer. In some cases, it's used alongside surgery. Radiation therapy usually requires a treatment each day, five days a week, for about five weeks. Each treatment takes only several minutes. This is called external or teletherapy. The entire pelvic area is irradiated by an x-ray beam usually generated by a linear accelerator. Everything in the pelvis is irradiated, bladder, rectum, large intestine, small intestine, bone and skin Bibbo, (1971). Following this treatment, a radioactive source is placed inside the cervix and vagina and left in place several hours or several days. This is called an implant, radium implant, intracavitary implant or any of several other names. A more accurate term is brachytherapy which means slow therapy. Often when cancer of the cervix is being treated with radiation, chemotherapy is also given to increase the effects of the radiation. Otherwise, chemotherapy is not used as initial treatment for cancer of the cervix. There are some investigational studies in which chemotherapy is given first and then either surgery or radiation performed, American Cancer society, (2016)

More advanced cases of cervical cancer are usually treated using a combination of chemotherapy and radiotherapy. Some of the treatments used have significant and long-lasting side effects, including early menopause and infertility. Surgery in mainstay of uterine cervical cancer therapy, tumors are cured by surgical removal and sometimes metastatic nodules which can be easily be excised. Presence of multiple metastases removal of primary tumor may help to relieve acute system. Eletrocautery is an ancient local heat treatment of benign disorders of female genital tract like chronic cervicitis. Cryosurgery is local cold treatment where energy transmitted in form of laser beam to treat intraepithelial neoplastic lesions of uterine cervix and vagina. Atopic application of broad spectrum antibiotic to cause massive desquamation of sq.epithelium of the cervix and vagina, FDA, (2014)

2.9.2 Cell Changes of Tissues Due to Cancer Treatment

Acute radiations effects were studied by Ruth gram on following cellular changes with marked cellular enlargement and nuclei, peculiar wrinkling of nuclei and vacuolization of the cytoplasm or nuclei and appearance of bizarre cells hyperchromasia in desquamated squamous. cells, Forman, (1974). Radiation effects on cancer cells have cellular and ballooning and extensive vacuolization of cytoplasm in a phenomenon called nuclear explosion. Chemotherapy,

successive treatment studied in a regression of histology show a mixture of Apoptosis and necrosis due to collapse of muscular supply or direct kill by chemotherapeutic agents .Suppression of immune system during organ transplant prevents rejection of transplanted organ has seen in chemotherapy cancers of several alkylating and chemotherapeutic agents, Forman, (1974)

2.9.3 Community Control and Prevention

Community may eradicate or prevent cancer of uterine cervix by practicing quality recommended marital habits that involves: avoiding early marriage that cause multiple births, avoiding first marital sex teens, avoiding multi marital partners ,encourage health education and have a mandatory annual routine pap test foe women above 17 years, also wiping from front to back after barrel movement. Use showers, instead of bath taps to avoid famine hygiene sprays, and scented touches, which irritate urethra. Screening of high risk groups and providing interventions to absolute cases is encouraged, FDA, (2014)

- i. Evidence suggests that HPV vaccines prevent HPV infection. The following 2 HPV vaccines ,
- ii. Gardasil vaccine from Merck, Whitehouse Station,: This quadrivalent vaccine is approved for girls and women 9-26 years of age to prevent cervical cancer and also genital warts and anal cancer caused by HPV types 6, 11, 16, and 18; it is also approved for males 9-26 years of age , FDA, (2014).
- iii. Cervarix vaccine, from GlaxoSmithKline, Research Triangle Park,: This bivalent vaccine is approved for girls and women 9-25 years of age to prevent cervical cancer caused by HPV types 16 and 18, FDA, (2014)

2.9.4 HPV Immunization and Vaccination:

- iv. Routine vaccination of females aged 11-12 years of age with 3 doses of either HPV2 or HPV4
- v. Routine vaccination with HPV4 for boys aged 11-12 years of age, as well as males aged 13-21 years of age who have not been vaccinated previously Vaccination with HPV4 in males aged 9-26 years of age for prevention of genital warts; routine, FDA, (2014)

3.0 Method and Apparatus

3.1 Study Design

Study design was descriptive quasi experiments, among women attending both out and inpatient gynecologic clinics for surveillance screening (early detection) and diagnosis. Saturated sampling design was used collect samples, also from private Pap test samples received from satellite facilities laboratory.

3.2 Apparatus

Basic apparatus and equipment were used during processing of specimen, staining and analysis. Auto clave was used to sterilize speculum, Binocular microscope at total magnification of 400

times was used for slides reporting and analysis, Distilled water and deionizer were used to purify water that constituted grades of alcohols, Speculum was used to expose posterior fornix before collecting pap smears, cytobrush to sample endocervical cells at 180 degrees, Cytobrooms was used to samples cell in sq. columnar junction, Baker and Silverton, (2001), France, (1988).

3.3 Experiment Material

3.3.1 Reusable Material:

Stout wall glass pipette with rubber bulb coloscope

- i. 22mm by 50 mm serrated slides
- ii. Assorted conical flasks
- iii. 22mm by 50 mm serrated slides
- iv. Assorted Beakers
- v. Examination table, Pasteur pipettes
- vi. Volumetric flasks of various capacities, metal forceps, staining jars, staining racks, filter funnels, heavy duty gloves, coping jars staining trays and Apron, Bakers and Silverstone, (2001)

3.3.2 Disposal Materials

Soap and detergent, disposal gloves, filter papers, labels and markers, Ayres spatula, cotton wool, gauze roll, aerosol spray in card board in slide mailer.

3.3.3 Biochemical Reagents and Stains

- i. DPX mountant,
- ii. 0.1% HCL or glacial acetic acid,
- iii. 0.5% hypochlorite, 95% ethyl alcohol,
- iv. Haris haematoxlin, Orange G.6 stain,
- v. Eosin azure 36 or 56,
- vi. 3% Lithium carbonate,
- vii. 1% acid alcohol
- viii. Xylene
- ix. Grades of ascending and descending alcohols, Baker and Silverton, (2001)

3.3.4 Female Precautions before Pap Tests

- i. Try not to have Pap test during menstrual periods
- ii. Avoid sex for 2 days before the test
- iii. Do not doache / wash inside the cervix, 2 days before the test
- iv. Do not use tampons, birth controls, foams, jellies or medicine in vagina for 2 days before the test, (American Cancer society,2016), France, (1988).

3.4 Procedure for Collecting Pap test/ Smear

A total of 400 respondents were used from both out patients and inpatient clinics. Counseled and informed patient on what test involved were told to seat on medical bed / couch and remove clothes up to waist, placed in lithotomic position, informed to open legs apart, after removing panty, Baker and Silverton, (2001). A speculum lubricated in saline or distilled water was inserted slowly in patient cervix through vagina while requesting her to relax muscle within pelvic region to expose external fornix of cervix (squamous –columnar junction), aspirated material cells at 360 degrees into pasture pipette or glass fitted on serrated labeled slide to make smears and immerse immediately into 95% alcohol to fix cells. Prescribed clinical request of the clients for Pap tests may include age, last menstrual period, number of parity life over death, quality Pap tests should be collected 7 days after the menstruation, for hormonal studies scrapings from proximal portion on lateral wall of vagina is recommended, Baker and Silverton, (2001).

3.5 Transportation of Pap tests to Central Laboratory

Specimens referred from satellite laboratories were collected in aerosol spray card boards, or in copling jars containing 95% alcohols into cytology laboratory.

Freshly removed cells need a minimum of 15 minutes of fixation in Absolute alcohol, to remove water from the tissue protein before staining, Baker and Silverton, (2001).

3.6.1 Macro and Microscopic Staining

Diagnosis of Pap tests is mainly determined by clinical history, blood stained smears are placed in 1N HCL or 1% acetic acid to haemolyse red cells before being processed ,Bakers and Silverstone, (2001)

3.6.2 Cells Processing

Specimen are given laboratory numbers through registering patient name in registry book, then the number is transferred on bottom of both pathological form and on the slide in written, using diamond pencil which make stencils on slide to avoiding being rubbed off during subsequence staining procedures, specimen collected in wards, contain IP no, which is written using pencil on cryostat slides, then transported in 95% alcohol. Bakers and Silverstone, (2001)

3.7 Pap Staining Principle

Haris haematoxyline, stain nucleus blue, Orange G 6, stain keratin, while eosin stain mature cytoplasm red, while light green stain immature cytoplasm, Papnicolau, (1948)

3.7.1 Pap staining Procedure

- i. “Bring slide to water” through descending grades of alcohols,
- ii. Immerse slide into haematoxlyn jar for 5 minutes

- iii. Gentle wash in running tap water to remove excess blue dye from slide.
- iv. Differentiate in 1% alcohol to remove basic stain from unwanted areas of cells.
- v. Transfer into O 6 Orange to stain keratin for 2 minutes, in light green to stain immature cells while in modified eosin (EA 36 / 50) to stain mature cytoplasm
- vi. Then dehydrate or remove water from the sections through ascending grades of alcohol, clear in xylene and mount in DPX mountant, Baker and Silverton, (2001).

3.7.2 Microscopic Pap test

Examine DPX mounted pap slides using lower objectives (x10 and x40)

5 - Scale of Reporting Pap test Results

- i. Absence of atypical / abnormal / cancerous cells Negative
- ii. Atypical cytology dysplastic , borderline but not plastic
- iii. Low Grade Squamous Intraepithelial Lesion (LSIL) with or without malignancy
- iv. High grade Squamous Intraepithelial Lesion, moderate or severe Cancer in Situ (CIS)
- v. Cytology conclusive of malignancy, where uterine cancer cells need Biopsy by colposcopy to confirmed Pap test in Histologically.

4.0 Results and Findings

4.1 Demographic Characteristics of Study Population

Demographic data consisted of mainly adult female patients attending Kenyatta National hospital (KNH) for Pap test diagnosis and screening .Using Saturated sampling design a total of 400 respondents were use to collect pap smear samples to examine for cancers and inflammation of genital tract system may be due to bacteria, fungi, protozoa and virus or unknown inflammation due to use of various methods of family planning.

Table I and **Fig 1** shows that age clusters of (37 – 46) yrs, and (27 -36yrs) form up the most (48%) affected cohorts by cancer uterine cervix due to their role of procreation and being sexual active in marriage. Also show that cancer may begin as early 17 years based on other health determinants or influences of attributed factors, such as inheritance or social cultural. However female below 17years have lower risks of developing uterine cancer of cervix compared to females above 37 years, with higher risk OD (0.002, 2.33).

4.2 Magnitude of Pap test Infestation and lesions Development in women Population

Table II and **Fig 2**, shows frequency distribution of Pap test samples processed and examined from the study area cytology laboratory, using prescribed clinical history for uterine cervical cancer, 48% of cases had both high and low grades of intraepithelial lesions while majority of cases (52%) had inflammation due to parasite infestations and infection while other cases had unknown cause of inflammation associated with method of family planning employed by various women in the study area. The pie chart shows prevalence of various microbes in female genitalia.

4.3 Overall Cancer Prevalence in Study Population

Table III and **Fig 3** show frequency distribution of pathogenic lesions diagnosed in the study population, since majority of patients came for diagnosis combined with late screening, thus Pap tests, results showed women have double risk of (32%) to developed HSIL than LSIL which is only 16%, RR (2.4, 1.2). This endangers life of the household thus, so the family and nation economic resources are jeopardized and declined towards achievement of the overall health goal in sustainable global goals.

4.4 Factors Attributed to Uterine Cervical Cancer.

Table IV and **Fig 4** indicate existence of reactive significance of health risk associated with women confirmed with Human Papiloma virus, Rapid antigen tests, with typical uterine cancer of cervix in Pap tests, compare to women who had physical warts on the vulva, where by their Pap tests were non reactive for Pap staining, due to absence of genes that cause cervical cancer in cells and tissues, thus minimal level of risk OD (4.9, 0.02) 95% CI (1.5, 0.3) to cause cancer.

5.1 Discussion

From the study results indicates that most of affect cohorts (37%) of female age lie in age (37 – 47) years which is attributed to their normal sexual action that fall in most fertile age of procreation, which is similar to biblical role of married families and their biological conjugal rights. Results also indicate most of affected women (32%), had low grade squamous intraepithelial lesions LSIL while high grade intraepithelial lesion HSIL was (16%) in Prevalence, which is similar with the study by first International Cancer cytopathology congress, Chigaco, 1956. Majority of women with full blown cancer of uterine cervix witnessed a variation of prescribed clinical information varying from pelvic inflammation diseases, besides painful coitus, majority were referred from tiers 3, 4 and 5 facilities, with confirmed reactive antigen and Pap tests for Human papiloma virus, similar to study by American Cancer Society, 2016, which confirms that cancer of uterine cervix is silence disease due to its silence signs and symptoms. Family planning methods had no significant relationships with developing of uterine cancer of cervix, with more chance to occur among women wearing IUDs that results to formation of Neobothian cyst in uterine cervix, this observation in line with the study by Forman, (1974), and Koss, (1959).

6.0 Conclusion and Recommendation

6.1 Conclusion

Prevalence of Human Papiloma virus and development of uterine cancer of cervix is very common in women of reproductive age between, (27-37) and (37 -47) years, in (SAA)

Study suggests implementation of primary prevention on Cancer diseases by households to be more effective and efficient compared to curative, palliative or rehabilitative management

6.2 Recommendation at Household level

Need for men involvement in the community screening of rapid HPV antigen test campaign and awareness, since they are silence carriers of HPV genes 16 and 18. Need for governments and Nations to decentralize Pap smear screening tests from tiers 5 and 6 to tiers 3 and 2 to enhance quality health care that is accessible and affordable to majority household in rural communities. Pap test services for early screening and detection of both cancer and antigens of HPV are paramount for rural households.

Current screening recommendations are determined by specific reproductive age, based on American Cancer Society guidelines, (2016):

- i. Females, below 17 years females No screening of pap test recommended
- ii. Females, between 17-29 years: need regular Cytology (Pap smear) alone every 3 years
- iii. Females, between 30 and 65 years: must go for Human papilloma virus (HPV) and cytology testing every 5 years, or Pap test alone every 3 years is recommended
- iv. Females above 65 years: No screening recommended if adequate prior screening has been negative and high risk is not present , American Cancer Society guidelines, (2016)

6.3 Immunization / Vaccination

Human Papiloma Virus (HPV) vaccines prevent HPV infection more effectively and efficiently among female and male aged below 26 years but negative for HPV antigen before. Common vaccines administered to eradicate or prevent HPV antigen epidemics include:

- i. Gardasil vaccine, immunization made from Merck, Whitehouse Station, an quadrivalent vaccine is approved for girls and women 9-26 years of age to prevent cervical cancer, also recommended for genital warts and anal cancer, due to HPV types 6, 11, 16, and 18; among males of 9-26 years of age.
- ii. Cervarix vaccine, made from GlaxoSmithKline, or Research Triangle Park, a bivalent vaccine for girls and women 9-25 years of age to prevent cervical cancer caused by HPV types 16 and 18 genotype
- iii. Routine Vaccines, immunization of females aged 11-12 years of age with 3 doses vaccine of either HPV2 or HPV4
- iv. Routine HPV4 vaccine administration for boys aged 11-12 years of age, as well as males aged 13-21 years of age who have not been vaccinated previously and are not infected before.
- v. HPV4 vaccine immunization among males aged 9-26 years of age for prevention of genital warts;

Acknowledgement

Completing of the article could not be possible, without contribution and support of a number of persons: Prof Wilson Odero, Prof. Emily Rogena, Prof Collins Ouma, Mr. Kariuki and Mrs. Susan Sitati, from Nairobi University, Maseno University, Ministry of Health Kenya, Kenyatta National Hospital and my supervisors from Kenya Medical Training College (KMTC) Nairobi, to what I greatly indebted

First and foremost I thank Kenya Defense Forces (KDF) and Kenyatta National Hospital Management for allowing me the opportunity and time to undertake studies in Kenya medical training College, Nairobi, Supervisors for their timely synergistic participatory assistance in reporting smears and writing

Secondly I extend my sincere gratitude to (KMTC) for offering me opportunity supervisors and academic support during the entire study period. Appreciate efforts and resources assistances provided by Ministry of Health facilities to collect data.

Finally I wish to express my thanks to all service providers in Kenya who volunteered time to participate in this study. Many people scarified their comforts to enable me produce this manuscript, I acknowledge all of them.

References

- American Cancer Society guidelines for the early detection of uterine cervical cancer, 2016
Baker and Silverton seventh edition, 2001, Introduction to Medical Laboratory 18: 244- 246
Bibbo M. Kecher 1971. Cytological diagnosis of repair in female genital tract
Gilbert .E and Palla 1966, Squamous papiloma of uterine cervix review and reports of giant papillary carcinoma 46:115-121
Gosforth .L 1953, Polyps and papiloma of cervix of uterine 1953
First intervention of Cancer of the cervix Congress in Chicago 1956, Metaplasia in uterine cervix a cytological correlation study in Tran's action
Forman M. 1974, Cellular change in glandular epithelium of patients wearing IUDs, source of cytological error
France Talaska 1988, Manual of Laboratory diagnostic Test, 3rd edition 11:656-659
Koss I.G and Wolinka 1959, Trichomonas Vaginalis cervitis and its attribution to uterine cancer of the cervix.
US Food and Drug Administration (FDA), 2014, approved bevacizumab (Avastin) for the management of persistent, recurrent or late-stage (metastatic) carcinoma of the cervix. This agent is approved for combination chemotherapy with paclitaxel and cisplatin or with paclitaxel and topotecan
Koprowsk 1975, Clinical histology an cytological aspects of warts – type genital lesion and association with cervical cancer. Biomedical aspects of Human warts virus infection
Macswen Whaley 13th edition 1992, Muir's text book of pathology 10: 374 378, 406.
Sonek M 1968, Vaginal cytology in childhood and puberty stage 2:39 -56, 198 -208
National Institutes of Health. Cervical Cancer. *NIH Consensus Statement*. 1996, 14:1–38.
NHS Cervical Screening Programme in UK ,2015

Papanicolau G. Marchet 1948. The epithelial of women reproductive system corrective study on cyclic change, using Pap stain, in New yolk

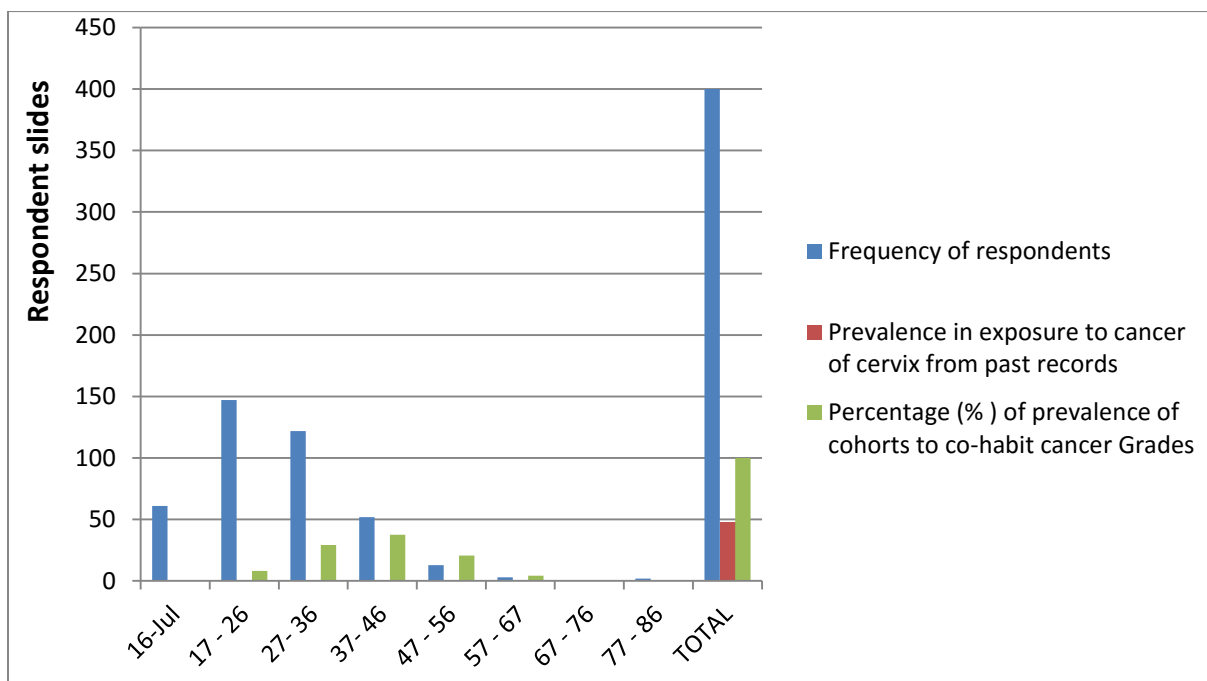
U.S. Cancer Statistics Working Group. *United States Cancer Statistics: 1999–2012 Incidence and Mortality Web-based Report*. Atlanta (GA):

Department of Health and Human Services, Centers for Disease Control (CDC) and Prevention, and National Cancer Institute; 2015.

William M. Rich, M.D, Clinical Professor of Obstetrics and Gynecology University of California, 201

Annexes

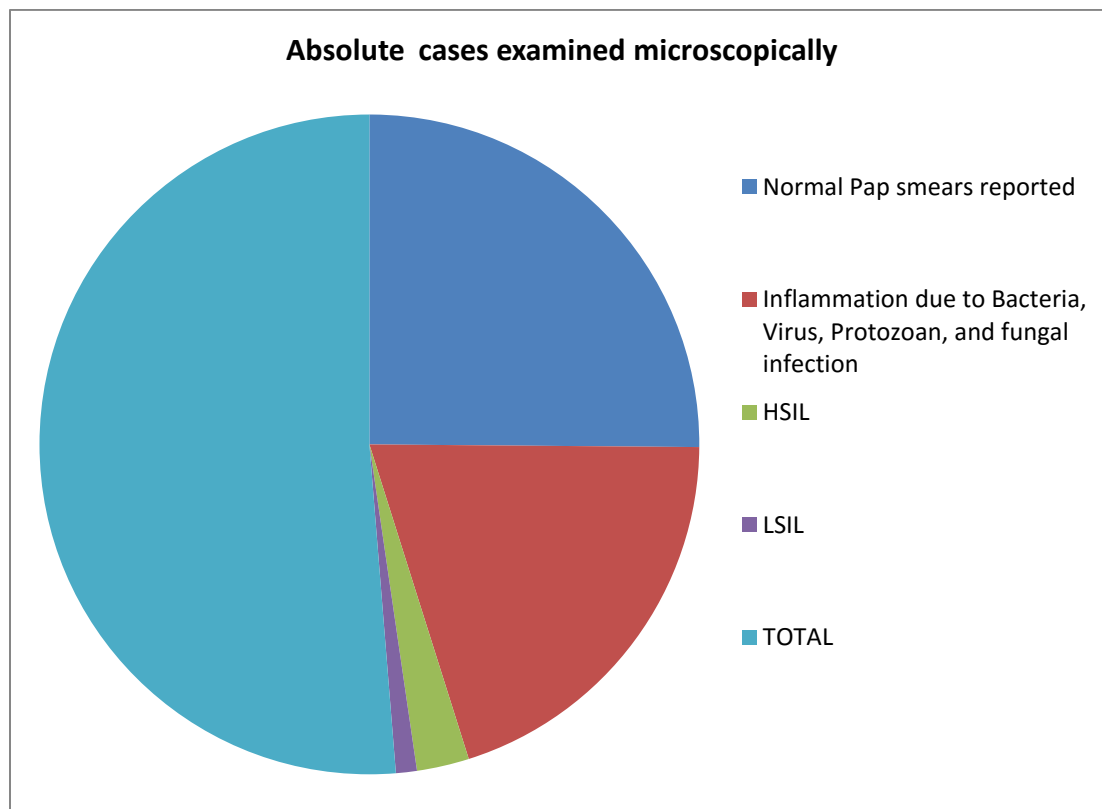
cohorts age in complete years	Frequency of Respondents	Prevalence of exposure to cancer of cervix from retrospective data	(%) of prevalence of cohorts in complete years
07- 16	61		0
17 - 26	147		8.3
27- 36	122		29.2
37- 46	52		37.5
47 - 56	13		20.8
57 - 67	3		4.2
67 - 76	0		0
77 - 86	2		0
TOTAL	400	48	100



1. **Table (I)** and **Fig 1** shows that age clusters of (37 – 46) yrs, and (27 -36yrs) form up most (48%) affected cohorts by cancer uterine cervix due to their role of procreation and being sexual active in marriage. Also show that cancer may begin as early 17 years based on other health determinants or influence of the attributed factors, such as inheritance or social cultural. However female below 17years have lower risks of developing uterine

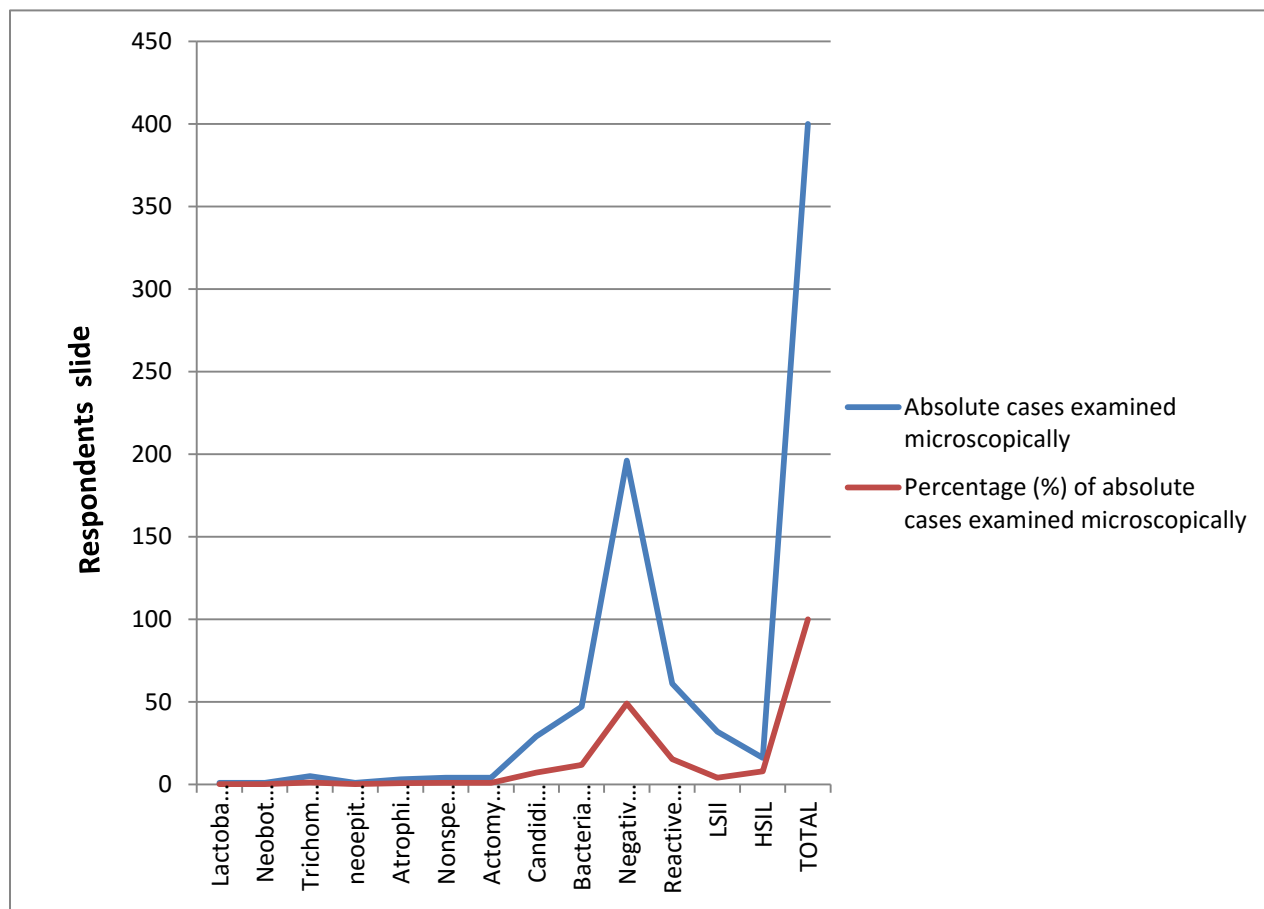
cancer of the cervix compared to females above 37 years, with higher risk OD (0.002, 2.33).

Grade / Stage of Cancer	Absolute Cases Examined Microscopically	Percentage (%)
Normal Pap smears reported	196	49
Inflammation due to Bacteria, Virus, Protozoan, and fungal infection	156	39
HSIL	20	
LSIL	8	
TOTAL	400	100



2. **Table (II)** and **Fig 2** shows frequency distribution of Pap test samples processed and examined from the study area cytology laboratory, using prescribed clinical history for uterine cervical cancer, 48% of cases had both high and low grades of intraepithelial lesions while majority of cases (52%) had inflammation due to parasite infestations and infection while other cases had unknown cause of inflammation associated with method of family planning employed by various women in the study area. The pie chart shows prevalence of various microbes in female genitalia.

Pathogenic Lesion	Absolute Cases Examined Microscopically	Percentage (%)
Lactobacilli	1	0.25
Neobothian cyst due to IDUs	1	0.25
Trichomonas vaginitis	5	1.25
neopithelial	1	0.25
Atrophic vaginitis	3	0.75
Nonspecific cervitisis	4	1
Actomyces	4	1
Candidiasis	29	7.25
Bacterial vaginosis	47	11.75
Negative/ normal smears	196	49
Reactive smears	61	15.25
HSII	32	8
LSIL	16	4
TOTAL	400	100



3 **Table III** and **Fig 3** show frequency distribution of pathogenic lesions diagnosed in the study population, since majority of patients came for diagnosis combined with late screening, thus Pap tests, results showed women have double risk of (32%) to developed HSIL than LSIL

which is only 16%, RR (2.4, 1.2). This endangers life of the household thus, so the family and nation economic resources are jeopardized and declined towards achievement of the overall health goal in sustainable global

Respondents clinical Data	Diagnosis made	Percentage of Diagnosis made
Surveillance smears positive with (HPV)	29	60.4
IDUs	5	10.4
Warts on genitalia	2	4.2
Secondary infertility	3	6.25
Uterine fibroids	2	4.2
Depo vera	1	2.1
Follow up LSIL	1	2.1
Normal screening	1	2.1
Amenorrhea	1	2.1
Follow up of highly risk group	1	2.1
Total	48	100

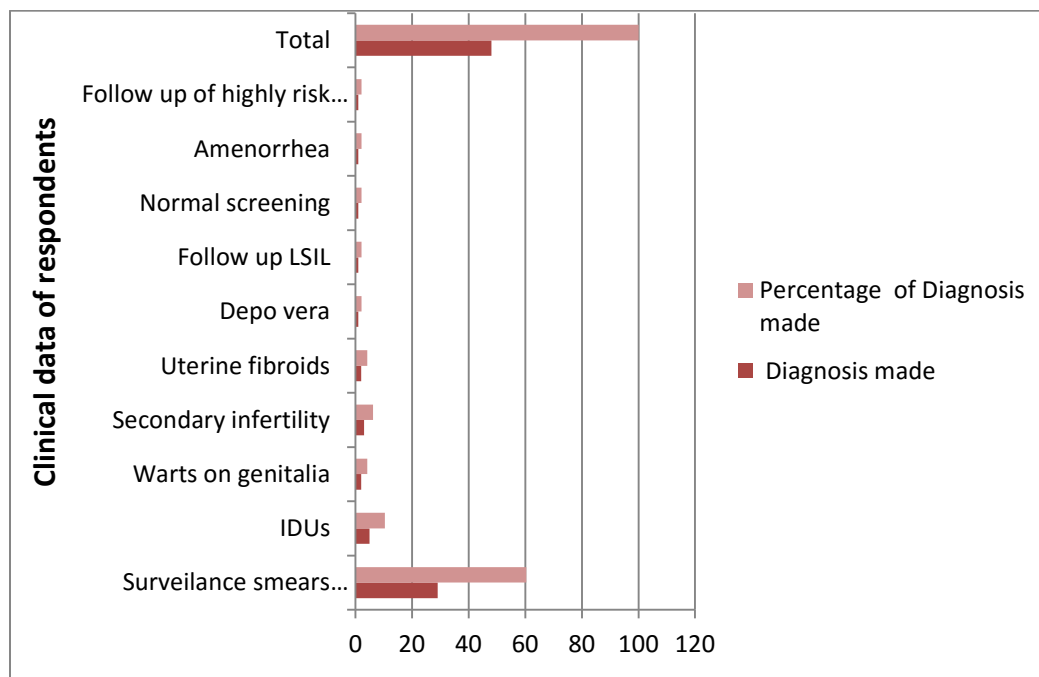


Table IV and **Fig 4** indicate existence of positive significance of health risk associated with women confirmed with Human Papiloma virus, Rapid antigen tests, with typical uterine cancer of cervix in Pap tests, compare to women who had physical warts on the vulva, where by their Pap tests were non reactive for Pap staining, due to absence of genes that cause cervical cancer in cells and tissues, thus minimal level of risk OD (4.9, 0.02) 95% CI (1.5, 0.3) to cause cancer.